



Difficulties in diagnosis of tuberculosis without bacteriological confirmation in a 15-year-old boy after the contact with a patient with tuberculosis – A case report

Teškoće u dijagnostici tuberkuloze bez bakteriološke potvrde kod 15-godišnjeg bolesnika dobijene kontaktom sa obolelim od tuberkuloze

Gordana Kostić*†, Raša Medović*†, Slavica Marković*†, Zorica Rašković*†,
Zoran Igrutinović*†, Vojislav Ćupurdija†‡, Marina Petrović†‡

Clinical Center Kragujevac, *Clinic for Pediatrics, †Center for Pulmonary Diseases,
Kragujevac, Serbia; University of Kragujevac, ‡Faculty of Medical Sciences,
Kragujevac, Serbia

Abstract

Introduction. After the contact with a patient suffering from tuberculosis (TB), previously healthy children have 1%–16% possibility to develop the disease. TB diagnosis in children is not easy to confirm so 15%–25% of cases remain undiagnosed. **Case report.** A 15-year-old-boy was hospitalized with productive cough, pain in the right flank area, fever, and fatigue, loss of appetite and night sweats. One of the boy's uncles was cured of tuberculosis, another uncle had active tuberculosis and both of them were in contact with the boy, but they did not live in the same household. During the physical examination, the child was febrile, with dyspnea, pale, with profuse sweating, debilitate. BCG (Bacillus Calmette – Guérin) scar was present. The auscultatory findings of the lungs showed quiet breathing from the scapula to the right lung base and chest radiography suggested massive right sided pleuropneumonia. The parameters of the inflammation were high and *Mycobacterium tuberculosis* (MTB) was not found in the samples of sputum and gastric lavage. Pleural puncture revealed

exudative nature in the aspirated fragment. Cytology was nonspecific, the MTB was not found and the planted surfaces on Lowenstein-Jensen remained sterile. Tuberculin skin test (TST) – Mantoux was positive (+ 10 mm), Interferon Gamma Release Assay (Quantiferon-TB GOLD In-Tube) was negative. The boy was unsuccessfully treated with broad spectrum antibiotics. By video-assisted thoracoscopy, the pleural tissue clip confirmed the benign chronic granulomatous process, while histochemical staining did not show MTB. The treatment with anti-TB medication led to clinical and radiographic recovery. The boy is now in good general condition, without consequences of the disease. **Conclusion.** This case report pointed out the importance of risk factors and difficulties in diagnosing TB in children.

Key words: tuberculosis, pulmonary; diagnostic techniques and procedures; diagnosis, differential; bacteriology; drug therapy.

Apstrakt

Uvod. Nakon kontakta prethodno zdrave dece sa obolelim od tuberkuloze (TB) mogućnost razvoja bolesti iznosi 1%–16%. Dijagnozu TB kod dece nije lako potvrditi tako da 15%–25% slučajeva ostaje nedijagnostikovano. **Prikaz slučaja.** Dečak star 15 godina hospitalizovan je zbog produktivnog kašlja, bola u desnom slabinskom predelu, povišene temperature, malaksalosti, gubitka apetita i noćnog znojenja.

Jedan dečakov ujak izlečen je od tuberkuloze, drugi ujak ima aktivnu tuberkulozu, obojica su bila u kontaktu sa dečakom, ali ne žive u istom domaćinstvu. Pri fizikalnom pregledu bolesnik je bio febrilan, dispnoičan, bled, sa profuznim znojenjem, adinamičan. BCG (Bacillus Calmette – Guérin) ožiljak je prisutan. Radiografija grudnog koša ukazivala je na masivnu desnostranu pleuropneumoniju. Parametri inflamacije su bili povišeni, a u uzorcima sputuma i gastričnog lavata nije nađen *Mycobacterium tuberculosis* (MTB). Pleuralnom punk-

cijom, utvrđeno je da je punktat eksudativne prirode. Citološki pregled bio je nespecifičan, nisu nađeni MTB i sve zasejane podloge na kulturi Lowenstein-Jensen ostale su sterilne. Tuberkulinski kožni test Mantoux bio je pozitivan (+10 mm). Interferon Gamma Release Assay (QuantiFERON-TB GOLD in-Tube) bio je negativan. Dečak je bez uspeha lečen antibioticima širokog spektra dejstva. Video-asistiranom torakoskopijom, isečak tkiva pleure potvrdio je da se radi o benignom, hroničnom granulomatoznom procesu, dok histohemijskim bojenjem nisu viđeni MTB. Započeto lečenje antituberkuloticima dovelo je do kliničkog

oporavka i radiografske regresije. Dečak je sada dobrog opšteg stanja, bez sekvela bolesti. **Zaključak.** Ovaj prikaz slučaja ukazao je na značaj faktora rizika, kao i otežano dijagnostikovanje TB kod dece. Auskultacijom pluća ustanovljeno je nečujno disanje od skapule desno ka bazi pluća.

Ključne reči:
tuberkuloza pluća; deca; dijagnostičke tehnike i procedure; dijagnoza, diferencijalna; bakteriologija; lečenje lekovima.

Introduction

Infection with *Mycobacterium tuberculosis* (MTB), does not always lead to active illness¹⁻⁵. After the contact of previously healthy children with people suffering from tuberculosis (TB), the possibility of development of active illness is 1%–16%. The highest risk is during the first two years after the infection and declines over time⁶⁻¹⁰. The symptoms of TB may arise from the respiratory tract, the cough longer than 2–3 weeks, chest pain, shortness of breath, blood coughing, or non-specific loss of appetite, fatigue, prolonged fever, chills, weight loss, night sweats^{1-5, 11}. In the pediatric intensive care units, 19% of all severe pneumonia develop from TB^{12, 13}, and the incidence of TB pleural effusion is about 16% of all pleural effusions^{14, 15}.

The diagnosis is based on history, physical examination, radiographic findings (chest X-ray and computed tomography), microscopy and culturing bacteria from sputum, gastric lavage, bronchoscopy, pleural puncture, or video-assisted thoracoscopy (VATS) of obtained content or tissue view, tuberculin skin test (TST), Interferon Gamma Release Assay (IGRA), response to the use of broad-spectrum antibiotics and physician assessment^{1-5, 12-18}. Because of the difficulty in obtaining adequate samples for laboratory tests, the diagnosis is not easy to confirm; 15%–25% of all suspected cases remain undiagnosed despite the use of combined diagnostic methods^{1, 5, 16}.

Case report

A 15-year-old boy was hospitalized at the Clinic of Pediatrics, Clinical Centre Kragujevac due to five-day productive cough, the pain in the right flank area and elevated temperatures up to 39°C. Twenty days before the admission to hospital the boy had a sense of fatigue, malaise, loss of appetite and night sweats.

History taking revealed two uncles with tuberculosis. One uncle was cured successfully three years ago, and the other was currently under treatment. The boy lived with his parents of middle socioeconomic status, away from the uncles, but he was in frequent contacts with them.

On the day of admission the boy's body mass was 49 kg (-5 kg), height 164 cm (P₂₅) with body mass index 18.22 kg/m² (P₂₅₋₁₀). He was aware, debilitate, febrile (38.2°C), pa-

le, with dyspnea and profuse sweating. Post vaccine Bacillus Calmette-Guerin (BCG) scar of 3 mm was present.

Chest respiratory movements were regular with a slight lag from the right. The auscultatory finding showed from the middle of the scapula to the right lung base treacherous muffled sound, with a weakened pectoral fremitus and inaudible breathing; oxygen saturation (SaO₂): was 93%.

Peripheral blood laboratory analyses showed: erythrocyte sedimentation rate 60 mm/h; hemoglobin – 107 g/L; leukocytes – 17.8 × 10⁹/L (lymphocyte dominance 10.2 × 10⁹/L); C-reactive protein (CRP) – 102.5 mg/L; fibrinogen – 5.151 g/L. Elevated levels of total cholesterol (5.91 mmol/L), low density lipoprotein (LDL) cholesterol (4.01 mmol/L) and triglycerides (2.32 mmol/L) were found. Other biochemical analyses were within normal range. IgM serologic result of the *Mycoplasma pneumoniae* was negative. Humoral immunity (IgM, IgG, IgA) showed normal values.

Chest X-ray showed large right sided pleural effusion up to the height of the 4th rib front corners (Figure 1).

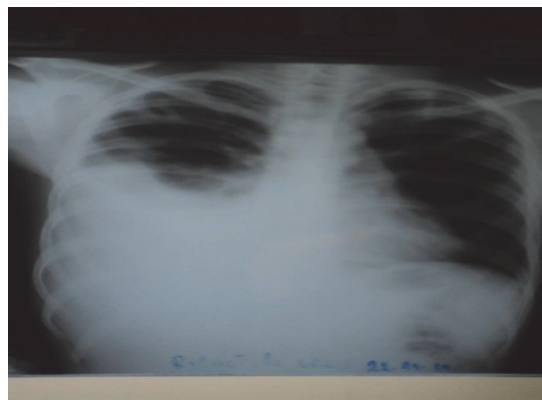

Fig. 1 – Chest radiography (X-ray) – large pleural effusion to the height of the front corners of IV ribs.

Ultrasonography of the abdomen showed that liver, gall bladder, pancreas, spleen, kidneys and bladder were normal. No free fluid or enlarged lymph nodes in the abdomen were found. Ultrasound examination of the heart showed the pericardium without pleural effusion. Due to radiographically revealed pleural effusion, the pleural puncture was performed and 500 mL of serohemorrhagic content was evacuated. The material was sent to biochemical, cytological and bacte-

riological analyses, staining by Zeihl-Neelsen method and seeding in Lowenstein–Jensen medium.

Cytological examination showed gray content with non-structured smear but with erythrocytes, lymphocytes, rare polymorphonuclear leukocytes and only a few macrophages and mesothelium cells.

Biochemical examination confirmed the exudative content in the pleural cavity. The ratio of proteins in the pleural aspirate/serum > 0.5 ($59/80$ g/L = 0.74), the ratio of lactate dehydrogenase (LDH) in the pleural aspirate/serum > 0.6 ($897/362$ U/L = 2.48) were found.

Neelsen staining did not show *Mycobacteria*, and planted surfaces on Lowenstein-Jensen medium remained sterile.

Tuberculin skin test (Mantoux) was positive (+10 mm), IGRA (QuantIFERON-TB GOLD in-Tube) test was negative. The treatment began with administration of broad spectrum antibiotics (cephalosporins of the third generation, macrolides, carbapenems), and bronchodilators, as well as the use of symptomatic treatments. After two weeks of treatment, there was a partial improvement of the clinical picture: reduction in symptoms (temperature decreased to 37.5°C , with less dyspnea), together with partial regression of radiological pleural effusion on the right side. Due to incomplete radiographic regression of pleural effusion and maintenance of subjective symptoms (night sweats, loss of appetite) VATS was indicated.

With this procedure, the clip of pleural tissue was taken for histological and Ziehl-Neelsen analyses. According to the histological analysis, benign, chronic granulomatous process was found, with parts of caseous foci, which could morphologically be tuberculosis process (according to the findings of pathologist at Military Medical Academy, Belgrade, Serbia).

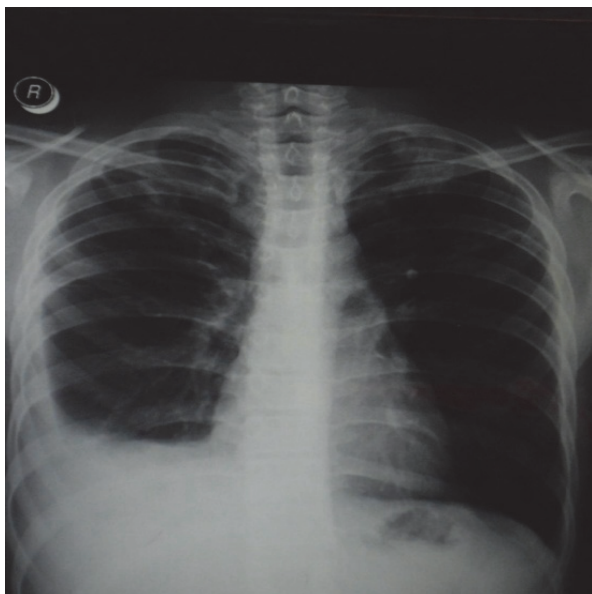


Fig. 2 – Chest radiography (X-ray) two weeks after the introduction of antituberculosis treatment.

Taking into consideration the above findings, and especially the fact that the boy had been in contact with TB

patients, clinicians decided to begin anti-tuberculosis treatment following the standard regime. The therapy included the first line drugs (isoniazid, rifampicin, pyrazinamide, ethambutol) and orally administered corticosteroids, H_2 -receptor blockers and vitamin B_6 . After a week of anti-tuberculosis treatment, significant clinical, laboratory and radiographic improvement was found (Figure 2), with the loss of symptoms (no fever, no night sweats), improvement of physical findings in the lungs and reduction of biohumoral inflammation parameters (SE – 10 mm/h, CRP – 1.9 mg/L).

After two months of initial antituberculosis treatment the chest radiography showed significant radiological regression of pleural effusion (right costophrenic sinus shaded with small shadow estuary, horizontal posterior was shown in the lateral part, the suspected small traction of the apical pleural on the right) (Figure 3).

After continual phase of the treatment (during four months and administration of two drugs), chest radiography showed complete radiographic regression of right sided pleural effusion.

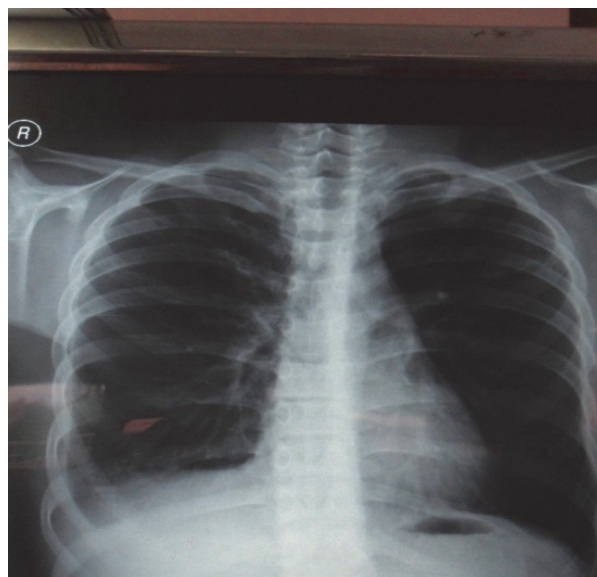


Fig. 3 – Chest radiography (X-ray) after two months of antituberculosis treatment.

Discussion

TB in children makes 5%–20% of the total, and about 74,000 children in the world die every year^{4, 19, 20}. According to Serbian Report on Tuberculosis, the morbidity rate in all age groups is 17 : 100,000, whereas the morbidity rate in children population is 6.425 : 100,000 with specific morbidity rate of 8.5 : 100,000 in the population aged 15–19 years²¹. After the contact with an adult suffering from pulmonary TB, the possibility of developing active disease is created in 1%–16% of previously healthy children with preserved immunity^{6–10}. Studies have shown that the different countries have different percentage of illness after the contact. The highest percentage of TB after the contact was found in the Netherlands study⁶ whereas much lower inciden-

ce of 3% was reported in a Chinese study ⁷, followed by considerably lower results in a Vietnam study (0.7%) ⁸ and 0.3% in a Norway study ¹⁰. These data indicate that the contact with the patient is not sufficient per se for the development of disease. The risk increases due to prolonged exposure, higher concentration of infected droplet nuclei MTB in the air, less volume of the joint space, lack of ventilation and direct sunlight and social factors ^{9,22,23}.

Most of the predisposing factors were present in our patient and recent contact with the TB patient was among the most important ones. The risk of development of the disease is highest during the first year of the contact and ranges up to 50% ^{6-10, 22, 23}. In the incidence of TB, genetic predisposition has an important role as well ^{24, 25}.

Although the diagnosis of TB in children is more difficult, according to Marais et al. ¹¹ classic clinical symptoms may indicate TB in children in almost 63% cases.

When parameters of increased inflammation are added to positive X-ray, the percentage of suspected TB increases to 80% ^{1, 4, 5, 16}.

In 87% cases, non-invasive methods such as chest radiography with elevated inflammatory parameters and a positive Tuberculin skin test confirm the diagnosis of tuberculosis ²⁶. Thorax computerized tomography (CT) is also recommended in cases of suspected TB. The boy's mother refused this proposed diagnostic procedure due to the risk of radiation, and several studies described the possibility of negative TB diagnostics after CT ^{1, 2, 4, 5, 16}, therefore we did not perform it. After the contact with a TB patient, Tuberculin Skin Test is positive in 50%–60% patients and the almost same percentage is with IGRA test. If the two tests are combined, the percentage is slightly higher ^{1, 2, 16, 17, 26, 27}. After special staining, the percentage of positive findings of sputum smear microscopy in children ranges from 1%–15%, and Lowenstein sown crops are positive in 10%–20% (and in best cases in children, it is 50%) ^{1, 2, 5, 16, 26}. Some researchers found that better results were obtained from seeding gastric lavage in comparison to sputum ²⁸. The test of nucleic acid amplification as well as the Xpert MTB/RIF (susceptibility testing for rifampicin) test are not performed in our center due to technical reasons, although a large group of experts in the countries with high prevalence of TB, such as India, no longer recommend them in diagnostics of TB in children ^{1, 19}.

It is recommended that TB is examined in each bronchopneumonia with pleural effusion. In addition, in TB pleurisy the inflammation is located in lungs in 20%–40%, which is not initially recognized in the lung radiography. For

larger pleural effusion, the thoracentesis is indicated due to diagnostic and therapeutic importance. In pleural aspirate during the cytological examination the mononuclear cells are found in 90%, and in 92% the definite diagnosis of this disease is histologically confirmed. In children, TB pleurisy has a good prognosis and it usually resolved without consequences ^{12, 14, 15}. This was the case with the patient we presented.

During the hospitalization of a child with severe pleuropneumonia and period for collecting the test results for confirmation of TB, it is necessary to administrate the initial antibiotic therapy in addition to other measures ^{12, 13}. Poor therapeutic response to broad spectrum antibiotics is the new protocol considered as another diagnostic guide for TB ^{1-5, 19, 20}.

After all diagnostic methods were exhausted in our patient, and when the treatment with broad-spectrum antibiotics began, the X-ray shadow of pleural effusion was still present; therefore it was decided to do VATS in order to confirm histopathological process. VATS was introduced as a diagnostic method for TB 15–20 years ago, but in the developing countries its application began just ten years ago ^{29, 30}. Even larger centers than ours do not apply it as a diagnostic method for TB, especially with children population ^{18, 30}. The indication should be considered in each particular case.

Despite the absence of TB bacteriological confirmation, due to the clear persistence of risk factors for developing TB, clinical symptoms, maintenance of elevated markers of inflammation besides antibiotic treatment and lung radiographic findings, antituberculosis therapy was administered and led to healing of the child.

There is no gold standard for TB diagnosis in some cases, and, sometimes positive clinical findings and epidemiological data are enough for beginning of antituberculosis treatment. Despite the use of the old and introduction of the many new diagnostic procedures, primarily the development of immunological tests (IGRAs false negative results in children according to some new data from literature), the global burden of TB diagnosis still remains significant ^{2, 4, 31, 32, 33}. In the presented case only the clinical suspicion of TB, a border level of TST (the criteria for positivity is 6–10 mm for BCG vaccinated patients) and chest radiography verifying severe bronchopneumonia were the criteria for introduction of antituberculosis therapy ^{1-5, 19, 20}.

Conclusion

This case report pointed out the importance of risk factors and difficulties in diagnosing TB in children.

R E F E R E N C E S

1. Kumar P, Kumar A, Lodha R, Kabra SK. Childhood tuberculosis in general practice. *Indian J Pediatr* 2015; 82(4): 368–74.
2. Ritz N, Curtis N. Novel concepts in the epidemiology, diagnosis and prevention of childhood tuberculosis. *Swiss Med Wkly* 2014; 144: w14000.
3. Marais BJ. Tuberculosis in children. *J Paediatr Child Health* 2014; 50(10): 759–67.
4. Hamzaoui A, Yaalaoui S, Tritar CF, Slim SL, Berraies A. Childhood tuberculosis: A concern of the modern world. *Eur Respir Rev* 2014; 23(133): 278–91.
5. González Saldaña N, Macías Parra M, Hernández Porras M, Gutiérrez Castrellón P, Gómez Toscano V, Juárez Olguín H. Pulmonary tuberculosis: Symptoms, diagnosis and treatment. 19-year experience in a third level pediatric hospital. *BMC Infect Dis* 2014; 14: 401.

6. *Sloot R, Schim van der Loeff MF, Kouw PM, Borgdorff MW.* Risk of tuberculosis after recent exposure. A 10-year follow-up study of contacts in Amsterdam. *Am J Respir Crit Care Med* 2014; 190(9): 1044–52.
7. *Jia Z, Cheng S, Ma Y, Zhang T, Bai L, Xu W, et al.* Tuberculosis burden in China: A high prevalence of pulmonary tuberculosis in household contacts with and without symptoms. *BMC Infect Dis* 2014; 14: 64.
8. *Thanh TH, Ngoc SD, Viet NN, Van HN, Horby P, Cobelens FG, et al.* A household survey on screening practices of household contacts of smear positive tuberculosis patients in Vietnam. *BMC Public Health* 2014; 14: 713.
9. *Gyawali N, Gurung R, Poudyal N, Amatya R, Niraula SR, Jha P, et al.* Prevalence of tuberculosis in household contacts of sputum smears positive cases and associated demographic risk factors. *Nepal Med Coll J* 2012; 14(4): 303–7.
10. *Dallner H, Ramm CT, Harstad I, Afset JE, Sagvik E.* Risk of developing tuberculosis after brief exposure in Norwegian children: Results of a contact investigation. *BMJ Open* 2012; 2(6): pii: e001816.
11. *Marais BJ, Gie RP, Hesselning AC, Schaaf HS, Lombard C, Enarson DA, et al.* A refined symptom-based approach to diagnose pulmonary tuberculosis in children. *Pediatrics* 2006; 118(5): e1350–9.
12. *de Pascale G, Bello G, Tumbarello M, Antonelli M.* Severe pneumonia in intensive care: cause, diagnosis, treatment and management: A review of the literature. *Curr Opin Pulm Med* 2012; 18(3): 213–21.
13. *Nantongo JM, Wobudeya E, Mupere E, Joloba M, Ssenooba W, Kiseambo HN, et al.* High incidence of pulmonary tuberculosis in children admitted with severe pneumonia in Uganda. *BMC Pediatr* 2013; 13: 16.
14. *Fischer GB, Andrade CF, Lima JB.* Pleural tuberculosis in children. *Paediatr Respir Rev* 2011; 12(1): 27–30.
15. *Nie H, Dai J.* Clinical value of pleural biopsy in the diagnosis of children with tuberculous pleurisy. *Zhonghua Er Ke Za Zhi* 2014; 52(5): 392–6. (Chinese)
16. *Rahman N, Pedersen KK, Rosenfeldt V, Johansen IS.* Challenges in diagnosing tuberculosis in children. *Dan Med J* 2012; 59(7): A4463.
17. *Sun L, Xiao J, Miao Q, Feng WX, Wu XR, Yin QQ, et al.* Interferon gamma release assay in diagnosis of pediatric tuberculosis: A meta-analysis. *FEMS Immunol Med Microbiol* 2011; 63(2): 165–73.
18. *Keys C, Mcleod E, Pesti C, Armstrong D.* Thoracoscopic pleural biopsy as an aid to diagnosis in pediatric tuberculosis with pleural involvement. *Eur J Pediatr Surg* 2012; 22(4): 315–7.
19. Working Group on Tuberculosis, Indian Academy of Pediatrics (IAP). Consensus statement on childhood tuberculosis. *Indian Pediatr* 2010; 47(1): 41–55.
20. *Berti E, Galli L, Venturini E, de Martini M, Chiappini E.* Tuberculosis in childhood: A systematic review of national and international guidelines. *BMC Infect Dis* 2014; 14 Suppl 1: S3.
21. The number of cases and deaths from infectious diseases. Institute for Public Health “Dr Milan Jovanović Batut”. 2014. Available from: <http://www.batut.org.rs/download/izvestaji/Izvestaj%20o%20zaraznim%20bolestima%202014.pdf>
22. *Nishimura M, Magawa K, Matsushita Y, Wakao I.* Importance of a symptomatic visit in tuberculosis contacts-classification of secondary cases. *Kekkaku* 2014; 89(7): 667–72. (Japanese)
23. *Rutherford ME, Hill PC, Mabarani W, Apriani L, Sampurno H, van Crevel R, et al.* Risk factors for Mycobacterium tuberculosis infection in Indonesian children living with a sputum smear-positive case. *Int J Tuberc Lung Dis* 2012; 16(12): 1594–9.
24. *Sia IG, Buckwalter SP, Doerr KA, Lugos S, Kramer R, Orilaza-Chi R, et al.* Genotypic characteristics of Mycobacterium tuberculosis isolated from household contacts of tuberculosis patients in the Philippines. *BMC Infect Dis* 2013; 13: 571.
25. *El Baghdadi J, Grant AV, Sabri A, El Azbaoui ES, Zaidi H, Cobat A, et al.* Human genetics of tuberculosis. *Pathol Biol (Paris)* 2013; 61(1): 11–6. (French)
26. *Luo WX, Huang Y, Li QB, Han J.* Values of a combination of multiple less invasive or non-invasive examinations in the diagnosis of pediatric sputum-negative pulmonary tuberculosis. *Zhongguo Dang Dai Er Ke Za Zhi* 2014; 16(8): 791–4. (Chinese)
27. *Hafizi H, Aliko A, Sharra E, Fico A, Migliori GB, Castiglia P, et al.* Results of a tuberculin skin testing survey in Albania. *J Infect Dev Ctries* 2014; 8(3): 310–4.
28. *Mukherjee A, Singh S, Lodha R, Singh V, Hesselning AC, Grewal HM, et al.* Delhi Pediatric TB Study Group. Ambulatory gastric lavages provide better yields of mycobacterium tuberculosis than induced sputum in children with intrathoracic tuberculosis. *Pediatr Infect Dis J* 2013; 32: 1313–7.
29. *Yim AP, Izzat MB, Lee TW.* Thoracoscopic surgery for pulmonary tuberculosis. *World J Surg* 1999; 23(11): 1114–7.
30. *Cozma G, Tudorache V, Burlacu O, Tunea C, Voiculescu V, Vancea D, et al.* Our experience in the thoracoscopic surgery of the tuberculous pleural effusions. *Pneumologia* 2007; 56(2): 73–6. (Romanian)
31. *Goletti D, Carrara S, Butera O, Amicosante M, Ernst M, Sauzullo I, et al.* Accuracy of immunodiagnostic tests for active tuberculosis using single and combined results: A multicenter TBNET-Study. *PLoS One* 2008; 3(10): e3417.
32. *Mandalakas AM, Detjen AK, Hesselning AC, Benedetti A, Menzies D.* Interferon-gamma release assays and childhood tuberculosis: Systematic review and meta-analysis. *Int J Tuberc Lung Dis* 2011; 15(8): 1018–32.
33. *Yassin MA, Petrucci R, Garie KT, Harper G, Teshome A, Arbide I, et al.* Use of tuberculin skin test, IFN- γ release assays and IFN- γ -induced protein-10 to identify children with TB infection. *Eur Respir J* 2013; 41(3): 644–8.

Received on March 22, 2016.

Revised on August 18, 2016.

Accepted on October 6, 2016.

Online First November, 2016.